



PATIENT
Emmy Lou Khorasani

SPECIES
Canine

BREED
Schnauzer Mix

SEX
Female Spayed

AGE
2 years

WEIGHT
11.5lbs

INTERPRETED BY
Maggie Machen
Lamy, DVM
DACVIM (Cardiology)

IMAGING PERFORMED BY
Pamela Harrigan,
RDCE

HOSPITAL NAME
Mass Veterinary Services

REFERRING VET
Dr. Masloski

INVOICE
31911

DATE
7/18/23

PRESENTING CLINICAL SIGNS

History: Emmy Lou is referred to evaluate a heart murmur. Good appetite and good energy level, active and playful. On exam: NSR, grade II/VI murmur with PMI left apical area, PSS, lung fields clear, mm pink, moist, CRT<2. BP: 130 - 140mmHg Currently, no medications. *Sedated with Propofol for study.

ECHOCARDIOGRAM FINDINGS

2D, m-mode, color flow and Doppler imaging is available.

Left ventricle: The LV diameter is normal with adequate myocardial function. LV wall thicknesses are normal.

Left atrium: The left atrium is normal.

Mitral valve: The mitral valve is mildly thickened with no prolapse into the left atrial lumen. Trace central mitral regurgitation.

Aortic valve/aorta: The aortic valve is normal in morphology and mobility. Normal aortic outflow velocity; laminar flow. No aortic insufficiency.

Right ventricle: Normal right ventricular diameter and morphology indicating no overt evidence of pulmonary arterial hypertension.

Right atrium: Normal RA dimension.

Tricuspid valve: The tricuspid valve appears normal with trivial tricuspid regurgitation; normal velocity.

Pulmonic valve/pulmonary artery: The pulmonic valve is normal in morphology and mobility. No pulmonic insufficiency. Normal RVOT velocity; laminar flow.

Pericardium/other: No pericardial or pleural effusion noted. No obvious cardiac masses.

Heart rhythm: ECG reveals a sinus rhythm with an average HR of 130bpm.

2-Dimensional Measurements

Ao diam (cm)	1.3
LA diam (cm)	1.4
LA:Ao (Swe)	1.1
IVS thickness (cm)	0.6
LVID diastole (cm)	2.2
PW thickness (cm)	0.6
LVID systole (cm)	1.5
FS (%)	32

Doppler Measurements

PV Vmax (m/s)	0.6
AoV Vmax (m/s)	0.9
MR Vmax (m/s)	NM
TR Vmax (m/s)	1.6
TR PG (mmHg)	11

INTERPRETATION OF THE FINDINGS

Early chronic degenerative valve disease is suspected with trace/mild mitral and tricuspid regurgitation. Lack of significant left atrial enlargement indicates the current risk for complication is low. No concurrent issues such as pulmonary hypertension are noted in this study.

Assessment of progression in the future will help predict long term prognosis, which is highly variable at this stage (B1).



PATIENT

Emmy Lou Khorasani

SPECIES

Canine

BREED

Schnauzer Mix

SEX

Female Spayed

AGE

2 years

WEIGHT

11.5lbs

INTERPRETED BY

Maggie Machen Lamy, DVM DACVIM (Cardiology)

IMAGING PERFORMED BY

Pamela Harrigan, RDCS

HOSPITAL NAME

Mass Veterinary Services

REFERRING VET

Dr. Masloski

INVOICE

31911

DATE

7/18/23

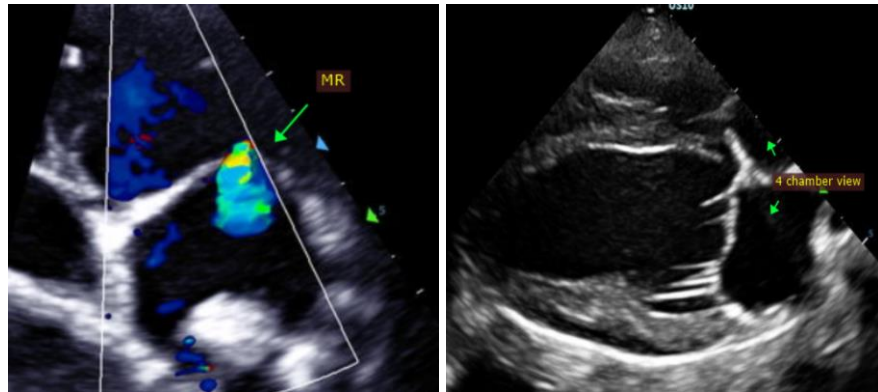
RECOMMENDATIONS

- In an asymptomatic dog without significant left atrial enlargement, no cardiac medications are clearly indicated.
- Omega fatty acid supplementation and mild salt restriction may be of some long-term benefit.
- No cardiac contraindication for general anesthesia.
- Monitor for development of a cough, labored breathing, exercise intolerance or collapse episodes.

PLAN

- Recommend conservative monitoring with a recheck echocardiogram in 1 year, sooner if any development of clinical signs.

IMAGES



The information and recommendations provided are based on the images presented by the referring veterinarian. No evaluation can be communicated regarding pathology that was not visible in the image/video clips provided.

Thank you for this referral. This report was generated using transcription software, and minor dictation errors may be present. If the clinical or image interpretation does not parallel your findings or if I can be of any further assistance, please contact me.

Maggie Machen Lamy, DVM
Diplomate of the American College of Veterinary Internal Medicine (Cardiology)
info@sonopath.com

Echocardiogram performed by: Pamela Harrigan, RDCS
Pet Animal Ultrasound Service (4paus.com)